



Para-implant residual cyst: A case report and review of the literature

***Corresponding Author: Irene Lafuente-Ibáñez de Mendoza & José Manuel Aguirre-Urizar**

Tel: +34-639480583; Email: Irene.lafuente@ehu.eus & josemanuel.aguirre@ehu.eus

Abstract

Residual Cyst (RC) is an odontogenic inflammatory pathology that appears at the site of a previous odontogenic inflammatory lesion. In this report, we present a 65-year-old male, with a history of pulpal pathology in tooth 2.5, which was extracted and treated with dental implants. He currently refers pain in the upper left maxilla with great peri-implant probing depth and marginal bone loss. During the surgical procedure, a para-implant lesion was discovered and sent for analysis. This corresponded to an odontogenic cyst without inflammation and a non-keratinized polystratified epithelial lining, with positive expression for CK14 and CK19. Final diagnosis was para-implant residual cyst. To date, five para-implant residual cysts have been described. These cystic lesions appear as an irregular radiolucency with marginal bone loss. In most cases, the implant remains stable after cyst removal. It is key to perform a good clinical history and radiological examination in patients with dental implants, as well as an active monitoring, in order to reach an early diagnosis of the peri-implant disorders.

Keywords: Dental implant; Bone-loss; Radiolucency; Residual cyst; Histopathology; Immunohistochemistry.

Introduction

Residual Cyst (RC) is an odontogenic inflammatory pathology, described in the latest WHO Classification of Head and Neck Tumours as a radicular cyst remaining in the jaws after the extraction of the affected tooth [1]. However, other odontogenic and non-odontogenic maxillary entities, cystic or neoplastic, can also mimic the radiological appearance of a residual cyst [2].

The RCs represent up to 10% of all odontogenic cysts and are mainly asymptomatic and slow-growing lesions [3]. The classical radiological appearance of RC is as a well-defined unilocular radiolucency with corticated margins [2], whose differential diagnosis includes other odontogenic entities such as lateral radicular cyst or odontogenic keratocyst. For these reason it is

Irene Lafuente-Ibáñez de Mendoza*; **José Manuel Aguirre-Urizar***;
Mikel Maeztu-Martínez; **Omar Fassi-Fihri**

Department of Stomatology II, University of the Basque Country, Leioa, Spain.

Received: Jan 04, 2024

Accepted: Feb 08, 2024

Published Online: Feb 15, 2024

Journal: Annals of Surgical Case Reports & Images

Online edition: <https://annscri.org>

Copyright: © de Mendoza ILI & Aguirre-Urizar JM (2024). This Article is distributed under the terms of Creative Commons Attribution 4.0 International License.

Cite this article: de Mendoza ILI, Aguirre-Urizar JM, Maeztu-Martín M, Fassi-Fihri O. Para-implant residual cyst: A case report and review of the literatura. *Ann Surg Case Rep Images*. 2024; 1(2): 1012.

very important to always perform a complete clinical history and radiological examination before the surgical enucleation [2]. In the last years, some RCs related to dental implants have been described.

Material and methods

A 65-year-old heavy-smoker man with poor oral hygiene and no medical history of interest, who referred pain in the upper left maxilla, associated with three dental implants placed 11 years ago (positions 2.4, 2.5 and 2.6). The patient had a history of a previous failed endodontic treatment in tooth 2.5 that left an irregular radiolucent lesion following the extraction, which was diagnosed as chronic periapical periodontitis (Figure 1A). After 7 years of implant placement, he had an episode of peri-implantitis and was treated with Er: Cr YSGG laser, after which



he stopped maintenance therapy. At the present, 4 years later, 2.5 and 2.6 implants show great marginal bone loss and 2.5 implant has a 10 mm buccal probing depth (Figure 1B). During the scheduled surgical treatment of peri-implantitis, a para-implant membranaceous lesion was discovered adjacent to the implant 2.5, with persistence of the bony septum of separation between the two bone defects (Figure 2).

Results

The histopathological analysis of the sample showed a well-defined cystic lesion with a dense fibrocellular connective tissue wall without inflammation, with a few well-defined remnants of odontogenic epithelium (Figure 3A-F). The cyst had a stratified non-keratinized epithelial lining, mostly thin with thicker areas with hyaline Rushton bodies. The immunohistochemical study showed positive expression of cytokeratins 14 and 19, confirming the odontogenic origin of the epithelial lining. With all these data, the final clinicopathological diagnosis was Para-implant Residual Cyst.

One year later, the patient remains under maintenance therapy for dental implants, with no further alterations. There are no signs of recurrence of the cystic lesion.

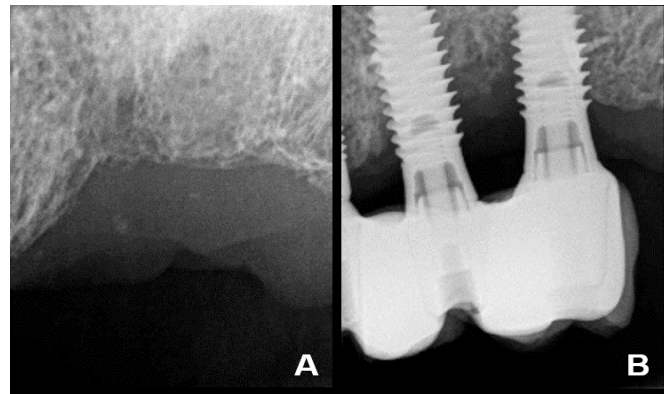


Figure 1: (A) Intraoral periapical radiograph showing an irregular radiolucency following tooth-extraction of 2.5 (2010). (B) Intraoral periapical radiograph revealing the marginal bone loss around implants 2.5 and 2.6 (2021).

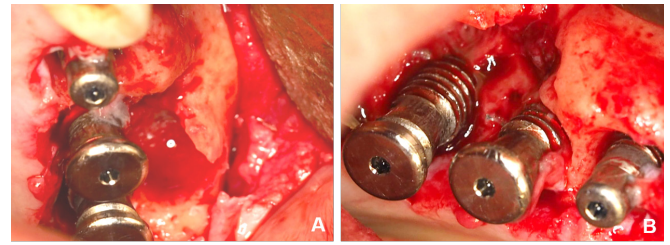


Figure 2: (A) Occlusal and (B) buccal view of the surgical approach showing a para-implant lesion adjacent to the implant 2.5.

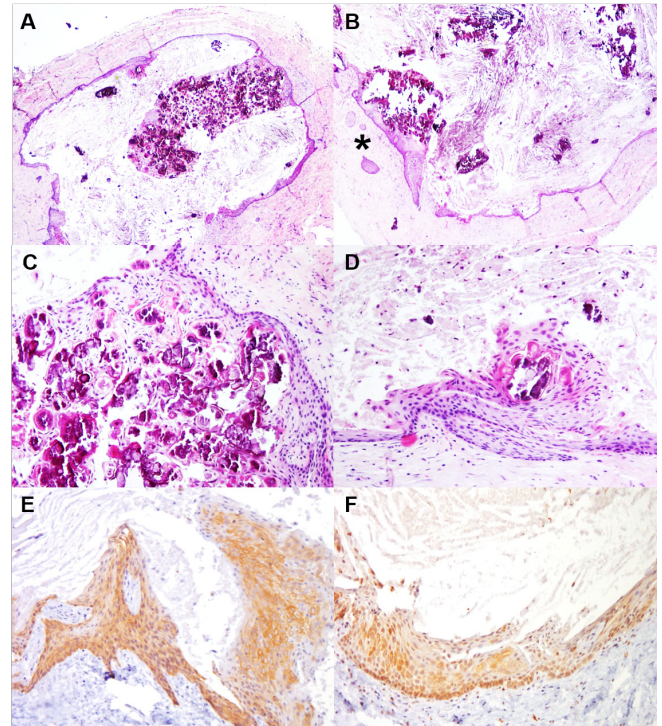


Figure 3: (A) Cystic lesion showing a dense connective tissue capsule without inflammation (H&E, 4x). (B) Cyst wall with well-defined epithelial odontogenic nests (star) (H&E, 10x). (C) Detail of the epithelial lining with Rushton bodies and calcifications (H&E, 20x). (D) Non-keratinised stratified epithelial lining and detritus in the cystic lumen (H&E, 25x). (E) Positive immunohistochemical expression of CK14 and (F) CK19 (25x).

Table 1: Main clinical data of cases of para-implant residual cysts.

Authors, year	Sex/ Age	Site	Endodontic history	Sign	Symptom
Frantz et al. 2014 [6]	F/59	Distal 1.2	Failed endodontic treatment	Purulent exudate in surgery	No
Pistilli et al. 2020 [7]	F/28	Buccal 1.2	Dental fracture	Swelling	Discomfort
Pistilli et al. 2020 [7]	M/25	Distal 3.7	Failed endodontic treatment	No	Discomfort
Pistilli et al. 2020 [7]	M/64	Distal 4.6	Unknown	Swelling	Discomfort
Current case	M/65	Buccal 2.5	Failed endodontic treatment	Purulent exudate in surgery	Discomfort

Discussion

The inflammatory RC is an odontogenic pathology that mainly appears in adult patients [4]. These lesions most frequently develop in the posterior sector of the mandible [3,4]. Given the absence of the initial inflammatory stimulus that triggered the radicular cyst, RC usually presents with a dense fibrocellular connective capsule and a milder inflammatory response [5]; in some cases indistinguishable from development odontogenic

cysts [2,3]. The thin epithelial lining of RC is non-keratinized and may show mucous metaplasia as well as different degrees of superficial keratinization, which can make the final histopathological diagnosis difficult [2]. The presence of Rushton hyaline bodies is also common in this pathology [1,2].

In this study, we present a special case of RC given its association with dental implants. This clinical scenario has motivated us to review the current scientific literature, in order to identify

other reported cases of RC associated with dental implants and to discuss its main clinic pathological features.

To date, four cases of para-implant RC have been published [6,7] (Table 1). The final five cases correspond to 2 females and 3 males, with a mean age of 48.2 years (range: 25-65). The lesions were located in the anterior and posterior sectors of the jaws. The time of evolution from implant placement until the diagnosis of the lesion ranged from 1 to 10 years. Para-implant RCs were mainly discovered as an irregular radiolucency associated with loss of peri-implant supporting bone. Most patients referred discomfort, and two of them also had a swelling at the site of the lesion. After the surgical excision, all dental implants maintained bone stability.

We believe that the pathogenesis of para-implant RC is similar to that of conventional RC. When the pulpal inflammatory process reaches the periapical region, a chronic inflammatory response in the periodontium leads to the activation and proliferation of the epithelial rest of Malassez, and the formation of a cystic cavity that remains in the bone after tooth-extraction [3]. The existence of a history of pulp pathology in all cases of para-implant RC (root-canal treatment failure, tooth-fracture) suggests that this factor is the starting point for these lesions, and not the inflammatory process of peri-implantitis itself. Nevertheless, the existence of a peri-implant inflammatory disorder could reactivate it.

This para-implant pathology once again highlights the importance of making a good clinical history and radiological analysis in all patients. It is also necessary to perform an adequate surgical curettage of the alveolus after tooth-extraction, in order to remove any material that may exist and always send it for microscopic study. When facing a maxillary radiolucent lesion, we must always proceed to its clinico-radio-histopathological diagnosis and treatment, prior to the dental implant placement. Same way, it should not be forgotten that “not all peri-implant inflammatory lesions correspond to peri-implantitis” [8]. Finally, although RC is an initially benign odontogenic disorder, cases of malignant transformation have also been reported in this pathology [9], which emphasize the importance of its correct diagnosis, treatment and control.

Conclusion

In summary, para-implant RC is an uncommon pathology but whose appearance justifies performing a complete clinical history and radiological examination in all patients undergoing dental implant therapy, and those who had a previous odontogenic inflammatory pathology. These patients should be actively monitored for early diagnosis and treatment of peri-implant disorders, including odontogenic cysts.

The patient previously signed an informed consent. This study follows the principles of the Declaration of Helsinki on Ethical Principles for Medical Research Involving Human Subjects, and has been approved by the UPV/EHU Research Ethics Committee (CEISH: M10/2016/057).

Acknowledgments: This research did not receive any specific grant from funding agencies in the public, commercial or not-for-profit sectors.

References

1. Speight P, Tekkeşin MS. Odontogenic cysts of inflammatory origin. In: El-Naggar A, Chan J, Grandis J, Takata T, Sloatweg P. WHO classification of head and neck tumours. Lyon: IARC Press. 2018; p232-233.
2. Shear M, Speight PM. Cysts of the oral and maxillofacial regions. 4rd ed. Oxford: John Wiley & Sons. 2007.
3. Main DMG. Epithelial jaw cysts: A clinic pathological reappraisal. *Br J Oral Surg.* 1980; 8(2): 114-125. [https://doi.org/10.1016/S0007-117X\(70\)80002-6](https://doi.org/10.1016/S0007-117X(70)80002-6)
4. Titinchi F, Morkel J. Residual cyst of the jaws: A clinico-pathologic study of this seemingly inconspicuous lesion. *Plos one.* 2020; 15(12): e0244250. <https://doi.org/10.1371/journal.pone.0244250>
5. Harris M, Toller P. The pathogenesis of dental cysts. *Br Med Bull.* 1975; 31(2): 159-163. <https://doi.org/10.1093/oxfordjournals.bmb.a071273>
6. Frantz BJ, Caton JG, Bonacci FJ, Geminiani A, Arseneau R, et al. Peri-Implant Cystic Lesion with Unusual Cellular Changes: A Case Report. *Clin Adv Periodont.* 2014; 4(4): 240-245. <https://doi.org/10.1371/journal.pone.0244250>
7. Pistilli R, Canullo L, Menini M, Pistilli V, Rossi-Fedele G, et al. Retrograde peri-implantitis associated with residual cysts: 3 Case reports. *JADA.* 2020; 151(12): 956-961. <https://doi.org/10.1016/j.adaj.2020.07.016>
8. Sotorra-Figuerola D, Lafuente-Ibáñez de Mendoza I, Parra-Pérez C, Aguirre-Urizar JM. Histopathological analysis of biopsies of “peri-implant inflammatory lesions.” Everything is not what it seems. *Clin Implant Dent Rel Res.* 2020; 22(3): 366-372. <https://doi.org/10.1111/cid.12905>
9. Van der Waal I, Rauhamaa R, Van der Kwast WAM, Snow GB. Squamous cell carcinoma arising in the lining of odontogenic cysts: report of 5 cases. *Int J Oral Surg.* 1985; 14(2): 146-152. [https://doi.org/10.1016/s0300-9785\(85\)80086-7](https://doi.org/10.1016/s0300-9785(85)80086-7)